

Mycoplasma agassizii Causes Upper Respiratory Tract Disease in the Desert Tortoise†

MARY B. BROWN,^{1*} ISABELLA M. SCHUMACHER,² PAUL A. KLEIN,³ KEITH HARRIS,⁴
TERRIE CORRELL,⁵ AND ELLIOTT R. JACOBSON²

Departments of Infectious Diseases¹ and Small Animal Clinical Sciences,² College of Veterinary Medicine,
and Department of Pathology and Laboratory Medicine, College of Medicine,³ University of Florida,
Gainesville, Florida; Armed Forces Institute of Pathology, Washington, D.C.⁴; and
The Living Desert Museum, Palm Springs, California⁵

Received 18 March 1994/Returned for modification 17 May 1994/Accepted 26 July 1994

The desert tortoise is listed by the United States government as a threatened species in part of its range. A major contributing factor in the decline of this animal has been the presence of an upper respiratory tract disease (URTD) which is characterized by a chronic disease which eventually leads to severe occlusion of the nares with viscous exudate and destruction of the respiratory epithelium. Electron microscopy of infected tissues demonstrated the presence of a mycoplasma-like organism attached to the respiratory surfaces. The mycoplasma was isolated and designated as a new species, with the proposed name *Mycoplasma agassizii*. The current study was designed to fulfill Koch's postulates and determine if *M. agassizii* was the etiologic agent of URTD. Clinically healthy animals with known antibody status were infused intranasally with pooled exudate ($n = 8$) from ill donor animals, with *M. agassizii* alone ($n = 9$) or in combination with *Pasteurella testudinis* ($n = 8$), with *P. testudinis* alone ($n = 9$), or with sterile broth ($n = 12$). The pooled exudate was culture positive for *M. agassizii*. Tortoises which received exudate or *M. agassizii* alone or in conjunction with *P. testudinis* were significantly more likely to develop clinical disease ($P < 0.0004$) than animals which received *P. testudinis* alone or the broth controls. Tortoises demonstrated a strong immune response to *M. agassizii*, and seroconversion was seen in all groups with clinical disease. *M. agassizii* was isolated from the upper respiratory tracts of clinically ill animals up to 6 months postinfection. On the basis of the results of these transmission studies, we conclude that *M. agassizii* is an etiologic agent of URTD in the desert tortoise.

Dramatic declines in the population of the desert tortoise, *Gopherus agassizii*, in the western Mojave Desert over the preceding 10 years resulted in designation of the animal by the Fish and Wildlife Service as environmentally threatened in 1990. Although a number of factors including habitat destruction, drought, and predation have contributed to the population decline, the appearance of an upper respiratory tract disease (URTD) was associated with major losses (8, 12). URTD has been seen in both captive (16) and wild (8) desert tortoises in the southwest United States and by us in captive and wild gopher tortoises (*Gopherus polyphemus*) in Florida. A similar disease has been seen in a variety of captive tortoises imported into England (9) and in tortoises submitted to the Veterinary Medical Teaching Hospital, University of Florida, of the following types: red-footed tortoise (*Geochelone carbonaria*), leopard tortoise (*Geochelone pardalis*), Indian star tortoise (*Geochelone elegans*), and radiated tortoise (*Geochelone radiata*). In desert tortoises and other tortoises, the disease is seen as a rhinitis characterized by an intermittent serous discharge flowing or bubbling from the nares. On some days the nares will appear dry. As the disease progresses, the discharge becomes more tenacious and contains large numbers of inflammatory cells and bacteria.

Fowler examined desert tortoises with respiratory disease and concluded that no single microorganism was responsible (4). In his opinion, continued stress, especially resulting from

malnutrition, was primarily responsible for the development of the disease. In another study, no major differences were observed in bacterial isolates from the respiratory tracts of captive and free-ranging desert tortoises (16). A bacterium belonging to the genus *Pasteurella* was isolated from the respiratory tract of both groups of tortoises, and eventually species status was proposed for these isolates under the name *Pasteurella testudinis* sp. nov. (15). Since this microorganism had been isolated from the respiratory tracts of ill and healthy desert tortoises, its significance was unknown.

Rhinitis also has been seen in long-term captive Mediterranean tortoises (*Testudo garrana* and *Testudo hermanni*), and a variety of microorganisms have been isolated from both ill and healthy tortoises of these species (9). As with desert tortoises, no major differences in bacterial isolations were noted. Because in many cases nasal swabs taken from tortoises with rhinitis do not yield bacteria, some investigators have suspected a viral agent as the cause of this disease (7). In another report, although not isolated from tortoises with rhinitis, mycoplasma was listed as a potential suspect microorganism (9).

In the 1970s, desert tortoises with signs of URTD were observed on the Beaver Dam Slope of Utah, a site where many captive desert tortoises were being released. In 1988, desert tortoises at the Desert Tortoise Natural Area, Kern County, Calif., were seen with clinical signs of illness similar to that of captive desert tortoises. Signs included a mucopurulent discharge from the nares, puffy eyelids, eyes recessed into the orbits, and dullness of the skin and scutes.

Recently, in examining free-ranging desert tortoises with URTD, we identified by electron microscopy a microorganism compatible with mycoplasma on the surface of the nasal

* Corresponding author. Mailing address: Department of Infectious Diseases, College of Veterinary Medicine, University of Florida, Gainesville, FL 32610. Phone: (904) 392-5961. Fax: (904) 392-7629.

† Journal series article R04049 of the Florida Agricultural Experiment Station, University of Florida, Gainesville.

mucosa of affected tortoises (8). A mycoplasma species (proposed *Mycoplasma agassizii* sp. nov.) was cultured from the nasal passageways of ill tortoises and was ultrastructurally similar to the pleomorphic microorganism seen in tissue section. The detailed description of this glucose-fermenting mycoplasma will be the subject of a later publication; however, the sequence of the 16S rRNA gene (GenBank accession number U09786) confirms that *M. agassizii* is a new species. Specific antibody to the mycoplasmal isolate correlated with the presence of lesions in the nasal mucosa (14), strongly suggesting an etiologic role for the mycoplasma.

Because of the previous high isolation rates of *P. testudinis* and the documented synergism of other infectious agents, including *Pasteurella* species, with mycoplasmas (1, 5, 13, 19), we designed a transmission study to determine if *M. agassizii* or *P. testudinis*, alone or in concert, could cause URTD in the desert tortoise.

MATERIALS AND METHODS

Tortoises. Sixty adult desert tortoises of both sexes and various weights (range, 1.5 to 4.6 kg) were acquired from the Desert Tortoise Conservation Center, Las Vegas, Nev., under special permit from the Fish and Wildlife Service. All tortoises were originally collected as wild tortoises in Las Vegas Valley and were considered healthy on the basis of physical examination and absence of clinical illness.

Individual outdoor pens (12 m²) were constructed in groups of five around palo verde trees at a remote site at The Living Desert Museum, Palm Desert, Calif. All pens were placed in a circle around the tree and were separated from adjacent pens by a solid metal barrier. All pens around a single tree composed a treatment group. Tortoises were fed daily a mixture of commercially available vegetables and had access to native vegetation growing in their pens. Water was provided ad libitum.

Tortoises were acclimated for 10 months prior to initiation of the study and allowed to undergo normal hibernation prior to initiation of the transmission study. During the acclimation period, eight tortoises became clinically ill and were removed from the study, one tortoise died, and one tortoise required euthanasia as a result of severe debilitation.

Prior to challenge, each tortoise was restrained manually and 2 ml of blood was collected from the jugular vein. Blood was added to lithium heparin microtainer tubes (Becton Dickinson, Franklin Lakes, N.J.) and inverted gently several times to prevent coagulation. Packed cell volumes were determined on a portion of the sample; the remainder of the blood was centrifuged, and the plasma was removed and frozen in cryotubes in liquid nitrogen for future antibody determinations. The area around the external nares was cleaned with sterile saline. Nasal washes were collected by gently flushing the nares with 1 ml of sterile tryptose broth (Remel Laboratories, Lenexa, Kans.) via a catheter attached to a syringe. Following collection, the nasal washes were placed in cryotubes, frozen in liquid nitrogen, and transported on dry ice to the University of Florida for processing.

Because the antibody level of each animal was known prior to the start of the infection study and because of the limited number of animals available, we were unable to completely randomize treatment. Pen groups with the lowest preexisting levels of antibody to *M. agassizii* were chosen to receive the critical infections of *M. agassizii* or *P. testudinis*.

Infection groups. Treatment groups are summarized in Table 1. Group I animals ($n = 9$) received 0.5 ml (0.25 ml per nostril) of *M. agassizii* grown in SP4 broth (18) to a concentra-

TABLE 1. Summary of treatment groups used in transmission study

Group	No. of tortoises	Treatment ^a
I	9	0.5 ml of intranasal <i>M. agassizii</i> (10^9 CCU/ml)
II	9	0.5 ml of intranasal <i>P. testudinis</i> (10^9 CFU/ml)
III	8	0.25 ml of intranasal <i>M. agassizii</i> (10^9 CCU/ml) and 0.25 ml of intranasal <i>P. testudinis</i> (10^9 CFU/ml)
IV	9	0.5 ml of intranasal exudate (pooled nasal secretions)
V	12	Control ^b

^a Tortoises were infused in the nares with infectious agent, exudate, or sterile broth control in the volumes noted.

^b The control group contained tortoises which were infused with 0.5 ml of intranasal sterile TSB used to grow *P. testudinis* ($n = 4$), 0.5 ml of intranasal sterile SP4 broth used to grow *M. agassizii* ($n = 3$), or no infusion (no intranasal challenge) ($n = 5$).

tion of 10^9 color-changing units per ml. The *M. agassizii* strain used was originally isolated from the nares of a desert tortoise with URTD (8), was filter cloned, and was two passages from the primary isolation. The purity of the isolate was determined on the basis of immunostaining and 16S rRNA sequence analysis. Group II animals ($n = 9$) received 0.5 ml (0.25 ml per nostril) of *P. testudinis* grown in brain heart infusion broth to a concentration of 10^9 CFU/ml. The *P. testudinis* strain used was originally isolated from the nares of a desert tortoise with URTD (16). Group III animals ($n = 8$) received 0.5 ml (0.25 ml per nostril) of an equal mixture of *M. agassizii* and *P. testudinis*. Because of the possibility that an unidentified infectious agent was responsible for the disease, group IV animals ($n = 9$) received 0.5 ml (0.25 ml per nostril) of exudate (pooled nasal secretions) derived from desert tortoises with active clinical URTD. *M. agassizii* was cultured from these exudates. Group V animals were control tortoises which received either 0.5 ml (0.25 ml per nostril) of tryptose soy broth ($n = 4$), SP4 broth ($n = 3$), or no intranasal challenge of any type ($n = 5$). For all groups, nasal infusions were performed via a catheter connected to a 1-ml syringe.

One additional group of tortoises ($n = 4$) in which one animal had high levels of antibodies to *M. agassizii* but never had any clinical evidence of illness was identified. To determine if this animal was an active carrier, the solid metal barriers separating adjacent pens were removed and tortoises were allowed to have both visual and physical contact through the fencing material. These tortoises did not receive any treatments. Although not technically part of the transmission study, these tortoises were observed for clinical signs and antibody production.

Postinfection monitoring of tortoises. Following infection, all tortoises were observed daily for clinical signs of URTD. Clinical signs of URTD included lethargy, change in behavioral and feeding habits, and physical signs such as runny or wet noses. At 1, 3, and 6 months postinfection, blood was obtained and processed as described above. In tortoises with rhinitis, nasal washings were collected and processed as described above.

Microbial cultures. Nasal washes were received at the University of Florida frozen on dry ice. Samples were placed at -70°C until processing. Samples were thawed at room temperature. Half of the sample was submitted to the Clinical Microbiology Laboratory, College of Veterinary Medicine, for routine aerobic cultures. The remainder of the wash was cultured for mycoplasmas. The wash was serially diluted 10-fold in SP4 broth, and a running drop was placed on SP4

agar (18). Because of potential bacterial contamination due to field sampling, a portion of the first dilution in SP4 broth also was filtered through a 0.45- μ m filter. Broth cultures were incubated at 30°C in ambient air. Agar was incubated at 30°C under 5% CO₂. Broth cultures were checked daily for acid production indicative of growth; agar plates were checked for growth at weekly intervals. All cultures were held for a minimum of 6 weeks. Isolations were most commonly seen at 3 weeks. Species confirmation was by growth inhibition with rabbit antiserum specific for *M. agassizii*. This antiserum did not cross-react with other known glucose-fermenting mycoplasmas, including *Mycoplasma testudinis*, *Mycoplasma pulmonis*, *Mycoplasma gallisepticum*, and *Mycoplasma pneumoniae*. In addition, selected isolates were confirmed on the basis of PCR amplification of the 16S rRNA gene followed by partial sequencing of the variable region of the gene.

ELISA procedure. The enzyme-linked immunosorbent assay (ELISA) procedure was performed as previously described (14). Briefly, *M. agassizii* PS6 was grown to mid-logarithmic phase in SP4 broth (18). Antigen was prepared by lysis of the cells in 0.05 M carbonate buffer, pH 10, for 30 min at 37°C followed by boric acid neutralization. The lysate was adjusted to 100 μ g of protein per ml and stored at -70°C until use.

Each well of a microtiter plate (Maxisorp F96; Nunc, Kamstrup, Denmark) was coated with 50 μ l of antigen at a concentration of 10 μ g/ml in phosphate-buffered saline (PBS) containing 0.02% NaN₃ (PBS/A) and incubated at 4°C overnight. The wells were washed four times with PBS/A containing 0.05% Tween 20 (PBSA-T) by an automatic ELISA washer (EAW II; SLT-Labinstruments, 5082 Groedig/Salzburg, Austria) and then blocked with 250 μ l of PBS/A containing 1% bovine serum albumin per well at room temperature for 60 min or at 4°C overnight. After four more washes, 50- μ l samples of plasma diluted 1:2 and 1:10 with PBS/A were added to individual wells in duplicate and incubated at room temperature for 60 min. The wells were washed again as described. Portions (50 μ l) of a biotinylated monoclonal antibody against desert tortoise immunoglobulin Y diluted 1:500 in PBS/A were added to the appropriate wells and incubated at room temperature for 60 min. After four washes, the wells were filled with 50 μ l of alkaline phosphatase-labeled streptavidin (AP-Streptavidin) (Zymed Laboratories, Inc., San Francisco, Calif.) (1:1,000 dilution in PBS/A) and incubated at room temperature for 60 min. After the wells were washed four times with PBS-T, 50 μ l of *p*-nitrophenyl phosphate disodium (Sigma, St. Louis, Mo.) (1 mg/ml prepared in 0.01 M sodium bicarbonate buffer, pH 9.6, containing 2 mM MgCl₂) was added to each well and incubated in the dark at room temperature for 60 min. The A₄₀₅ of each well was determined in an ELISA plate reader (EAR 400 AT; SLT-Labinstruments). In each assay, the blank was the mean of two wells coated with antigen and incubated with the conjugate and the substrate only. Plasma of a desert tortoise, culture negative for *M. agassizii* and free of lesions indicative of URTD, was the negative control. Plasma from a desert tortoise infected with *M. agassizii* and having lesions indicative of URTD was the positive control. Positive and negative controls were included on each plate to determine interplate variation. All antibodies used in the ELISA were biotinylated. Antibody levels were expressed as the ratio of the A₄₀₅ of the sample to the A₄₀₅ of the negative control (8).

Pathological evaluations. Representative tortoises (*n* = 4) from each infection group were euthanized with a concentrated barbiturate solution and necropsied. The head of each tortoise was bisected longitudinally. Swab specimens of the nasal mucosa were taken for mycoplasmal and microbial

TABLE 2. Outcome of transmission study to determine pathogenicity of *M. agassizii* and *P. testudinis* in the desert tortoise

Infection group and treatment ^a	Ratio with clinical signs (%) ^b	Ratio with seroconversion (%) ^c	Ratio with <i>M. agassizii</i> isolation (%) ^d
I MA alone	8/9 (89)	9/9 (100)	5/7 (71)
II PT alone	1/9 (11)	1/9 (11)	0/1 (0)
III MA + PT	7/8 (87)	8/8 (100)	3/5 (60)
IV Exudate ^e (<i>n</i> = 8)	8/8 (100)	6/8 (75)	5/7 (71)
V Control ^f (<i>n</i> = 12)	3/12 (25)	2/12 (17)	0/3 (0)
Broth (<i>n</i> = 7)	2/7 (29)	1/7 (14)	0/2 (0)
No treatment (<i>n</i> = 5)	1/5 (20)	1/5 (20)	0/1 (0)

^a MA, *M. agassizii*; PT, *P. testudinis*.

^b Groups receiving exudate or *M. agassizii* alone or in conjunction with *P. testudinis* were more likely to develop clinical disease, *P* < 0.0004; number with signs/number in group.

^c Number that seroconverted/number in group. An animal was deemed to have seroconverted if the specific antibody as measured by ELISA either (i) increased from a negative to a positive value or (ii) the value increased by >0.1 ELISA unit during the course of the study.

^d Isolation of *M. agassizii* was determined on the basis of direct culture of nasal flushes obtained from live animals which showed active clinical signs and is expressed as number with *M. agassizii*/number with active clinical signs. The isolates were confirmed as *M. agassizii* by a positive reaction with specific antiserum.

^e One tortoise which received exudate died.

^f Tortoises in the control group received either sterile broth or no infusions.

isolation. One side of each bisected head was fixed in neutral buffered 10% formalin, decalcified, embedded in paraffin, sectioned longitudinally at 7 μ m, stained with hematoxylin and eosin, and examined by light microscopy. All samples were examined by a single pathologist, and the infection group to which a section belonged was not known. Lesions were classified as normal (no lesion), mild (no edema, limited numbers of inflammatory cells), moderate (moderate edema, moderate numbers of inflammatory cells with occasional incursion into the overlying mucosa, some disorganization of basal epithelium), and severe (marked edema, large numbers of inflammatory cells with incursion into the overlying mucosa, marked degeneration and necrosis of the basal epithelium).

Statistical analysis. Binomial data were analyzed by the chi-square test. All other data were analyzed by analysis of variance, followed by Duncan's multiple range test used to determine differences among means. A *P* value of ≤ 0.05 was accepted as significant.

RESULTS

Clinical disease observations. Tortoises which received exudate or *M. agassizii*, alone or in conjunction with *P. testudinis*, were more likely to develop clinical disease (*P* < 0.0004 [Table 2]). Control groups and tortoises which received *P. testudinis* alone did not develop clinical disease.

All but one tortoise which received *M. agassizii* (group I) developed clinical disease, but only three tortoises were reported to be down (inactive or spending excessive time in their burrows) during the study. *M. agassizii* was recovered from five of seven tortoises with clinical disease in group I. Seroconversion to *M. agassizii* was seen in all group I tortoises (Table 2).

Infection with *P. testudinis* alone (group II) did not result in clinical disease (Table 2). One tortoise in this group had clinical signs of disease; however, this tortoise also demonstrated a rise in levels of antibody to *M. agassizii* a few weeks after clinical signs of illness were noted. However, attempts to isolate the mycoplasma were unsuccessful.

Although no tortoises which received both *M. agassizii* and *P. testudinis* (group III) were reported as down, seven of eight did develop clinical disease. It should be noted that these animals received half the amount of *M. agassizii* that animals in group I received, which could explain the less severe disease seen in this group. Seroconversion to *M. agassizii* was seen in all group III tortoises (Table 2).

Tortoises which received exudate (group IV) developed the most severe clinical signs. Six of eight tortoises were reported as down at some point during the study. One animal died but was not available for necropsy. Only two animals in group IV failed to demonstrate increased levels of antibody to *M. agassizii*. Both of these tortoises had initial levels of antibody to *M. agassizii* which remained stable and did not increase or decrease significantly.

No significant disease was seen in control animals (group V). Two broth control tortoises developed clinical signs of disease; signs were transitory in one animal but persistent in the other. Neither animal developed antibody to *M. agassizii* or had the mycoplasma isolated from nasal washes. One control animal which received no broth or other treatment developed clinical signs and demonstrated a rise in levels of antibody to *M. agassizii*, but attempts to culture *M. agassizii* were unsuccessful. This was the only control tortoise to be reported down and not active during the study.

Histopathology and lesion analysis. No significant lesions were observed in the control animals. Severe lesions were seen in all tortoises which received exudate ($n = 4$). In the group which received *M. agassizii* alone, severe lesions were seen in one, moderate lesions were seen in two animals, and mild lesions were seen in one animal. In the group which received both *M. agassizii* and *P. testudinis*, moderate lesions were observed in all tortoises.

Sections from the mucous and olfactory mucosae of normal control tortoises (Fig. 1) showed occasional small subepithelial lymphoid aggregates. Heterophils were rarely observed in the laminae propriae. No changes in the mucosal or glandular epithelia were noted, and no edema was observed. A lesion was characterized as mild inflammation (Fig. 2A) if multifocal, small subepithelial lymphoid aggregates were seen, if the lamina propria contained multifocal small numbers of heterophils, lymphocytes, and plasma cells, and if mild edema was seen in the lamina propria and minimal changes were noted in the mucosal epithelium. A lesion was classified as moderate (Fig. 2B) if multifocal to focally extensive lymphoid aggregates were observed, if diffuse, moderate numbers of heterophils, lymphocytes, and plasma cells which occasionally infiltrated the overlying mucosal epithelium were seen, and if moderate edema was noted in the lamina propria with proliferation and disorganization of the basal epithelium. A lesion was classed as severe (Fig. 2C) if focally extensive to diffuse bands of lymphocytes and plasma cells subjacent to and obscuring the overlying mucosal epithelium were seen, if large numbers of heterophils were found in the lamina propria and infiltrated the overlying mucosal epithelium, if the lamina propria was characterized by marked edema, if there was degeneration, necrosis, and loss of the mucosal epithelium with occasional erosion, and if proliferation of the basal cells of the epithelium with metaplasia of the mucous and olfactory epithelium to a basaloid epithelium was observed; occasional squamous metaplasia was also noted.

Antibody levels. A significant ($P < 0.004$) rise in antibody to *M. agassizii* was observed in tortoises receiving exudate as early as 1 month postchallenge (Fig. 3). Tortoises which received *M. agassizii* alone or in conjunction with *P. testudinis* also developed an antibody response, but the response was not observed

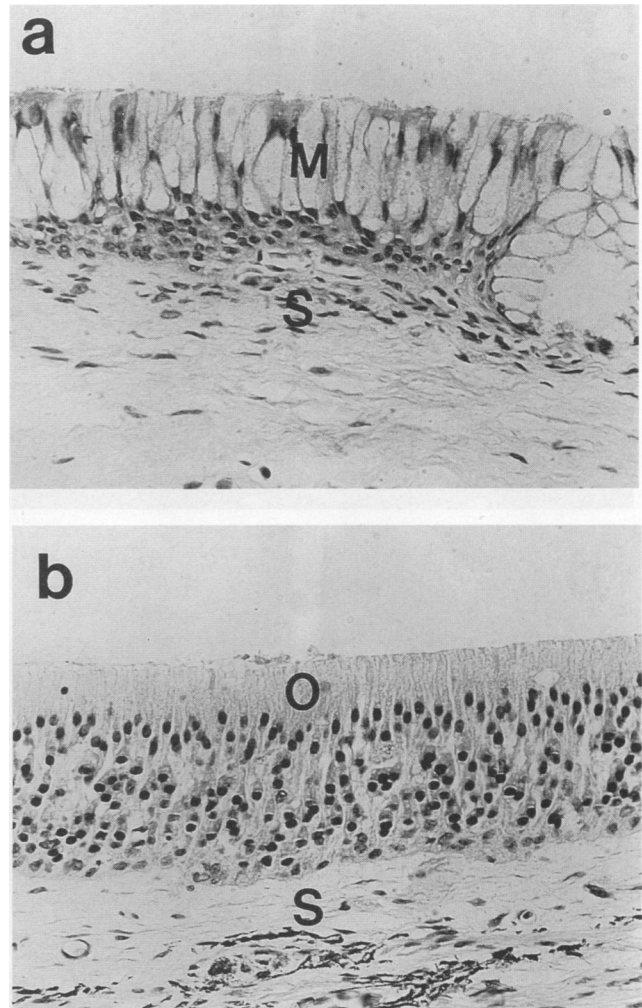


FIG. 1. Photomicrograph of the nasal cavity of a clinically healthy desert tortoise. (a) An area of mucous and ciliated epithelial cells (M) overlying a lamina propria submucosa (S) primarily consisting of connective tissue and small vessels. (b) An area of multilayered olfactory mucosa (O) overlying a lamina propria submucosa (S) consisting of connective tissue, vessels, and melanophores. Stain, hematoxylin and eosin; magnification, $\times 230$.

as early as with exudate-challenged animals. By 3 months postinfection, tortoises which received *M. agassizii* (groups I and III, Table 1) had significantly higher antibody levels than did animals which received sterile broth (group V) or *P. testudinis* alone (group II). No difference in levels of antibody between animals receiving *M. agassizii* alone or in concert with *P. testudinis* was seen; however, tortoises which received the exudate did develop higher responses at 3 months postinfection than did those tortoises which received *M. agassizii* ($P < 0.01$).

DISCUSSION

Diseases caused by pathogenic microorganisms are an ever-present risk to animals in both captive and wild populations, especially during periods or conditions of captive breeding followed by release or translocation or ecosystem perturbation and habitat loss or fragmentation (6, 10, 11). Infectious diseases, their impact on population health, health status, and

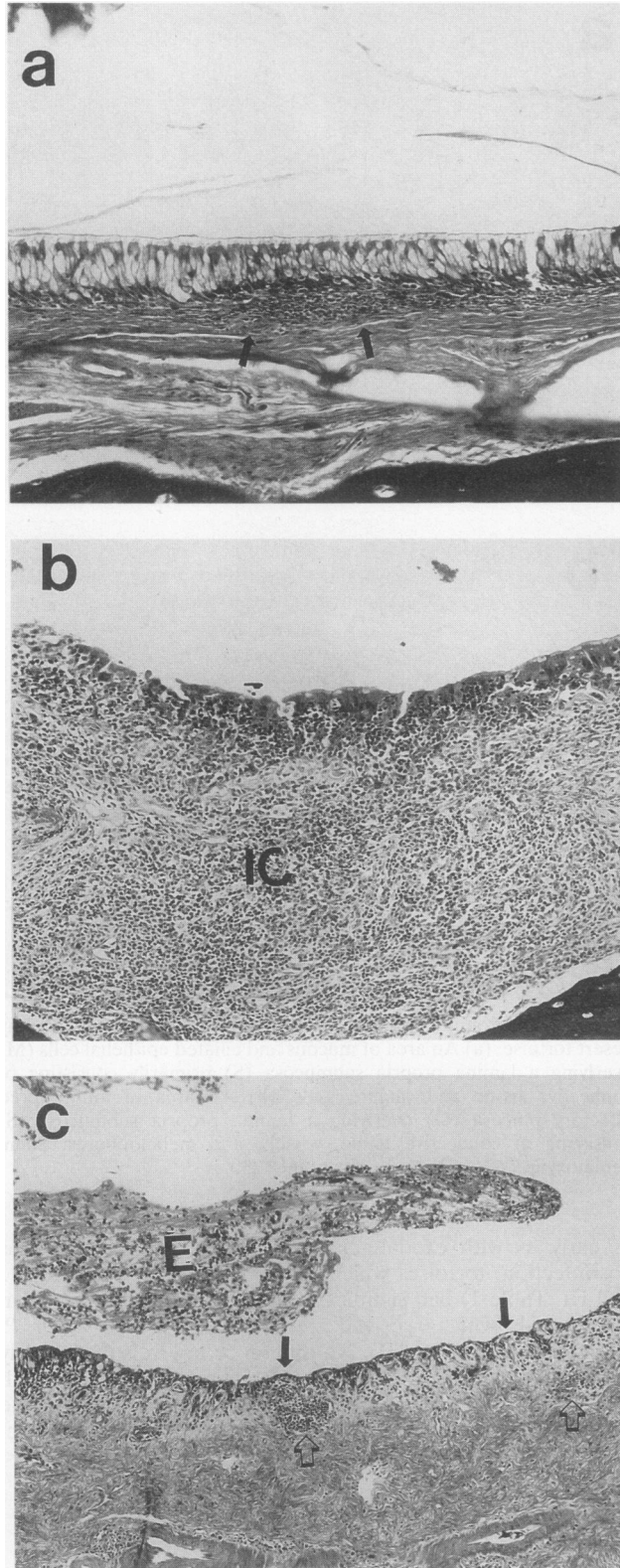


FIG. 2. Representative lesions observed in the upper respiratory tracts of experimentally infected desert tortoises. (a) Mild lesion in the choana characterized by infiltrates of lymphocytes and plasma cells into the lamina propria (arrows). Note that the overlying epithelium is intact. Stain, hematoxylin and eosin; magnification, $\times 113$. (b) Moderate lesion in the nasal mucosa characterized by a dense mixed

population health monitoring, and the consequences of relocation or translocation on health are rarely considered in implementation and design of conservation projects. URTD in the desert tortoise is a prime example of the importance of infectious agents to population health in free-ranging wildlife. Because clinical disease may be silent, relocation of tortoises can pose health risks to other tortoise populations. Similarly, release of captive tortoises into wild populations could spread disease.

A major contributing factor in the decline of the desert tortoise and its federal listing as environmentally threatened has been the presence of URTD. Animals have a chronic disease which eventually leads to severe occlusion of the nares with viscous exudate and destruction of the respiratory epithelium (8). Electron microscopy of infected tissues (8) and association of antibody specific to *M. agassizii* (14) suggested, and the current study proves, a mycoplasmal etiology for URTD. Mycoplasmas cause respiratory disease in a number of animals including humans, rodents, pigs, and poultry (1). Although the species of mycoplasma which causes disease is different for each host, there are many common characteristics of the disease and URTD in desert tortoises shares many of these characteristics. Many apparently normal animals may carry the mycoplasmas without obvious ill effects (1). Disease caused by mycoplasmas is often clinically silent, slowly progressing, and chronic. The severity of the disease is exacerbated by environmental factors and stress, and other microbial agents may act synergistically to create even more severe disease (1, 5, 13, 19). URTD in the tortoise presents a very similar profile, with the presence of seemingly healthy animals which break with the disease after the stress of relocation or crowding. The types of lesions seen in other mycoplasmal respiratory infections also share many characteristics with URTD in the tortoise. In rats, *Mycoplasma pulmonis* causes focal loss of ciliary action, followed by extensive loss of epithelial cell layers with eventual complete destruction of the respiratory epithelium (1, 17). This is also seen in URTD (8). Most respiratory mycoplasmal infections are characterized by an increase in inflammatory cells, especially neutrophils. In tortoises, foci of inflammatory cells are seen (8). In electron micrographs, mycoplasmas frequently can be seen attached to the respiratory epithelium just above these areas of inflammation.

The most stringent requirements for establishment of the etiological role of an infectious agent in disease is the fulfillment of the Henle-Koch-Evans postulates (2, 3). Although it is particularly difficult to fulfill these postulates for a chronic disease in a free-ranging wild animal, the major postulates have been met. The initial *M. agassizii* isolate was obtained from the choana of a tortoise with clinical disease (8). Disease as evidenced by histological lesions was present significantly more often in exposed animals, as determined by both culture and serology (14). In the present study, the mycoplasmal isolate was cultured in vitro and produced clinical disease when

inflammatory cell infiltrate (IC) composed primarily of lymphocytes with few plasma cells, macrophages, and heterophils. Note that the overlying epithelium is disorganized and obscured by inflammatory cells. Stain, hematoxylin and eosin; magnification, $\times 113$. (c) Severe lesion of the nasal sinus characterized by erosion of the normal epithelium (closed arrows) with the remaining epithelium composed of basaloid or squamous cells. Edema and mixed inflammatory cell infiltrates are seen (open arrows). Note the exudate (E) in lumen composed of heterophils and fibrin. Stain, hematoxylin and eosin; magnification, $\times 75.0$.

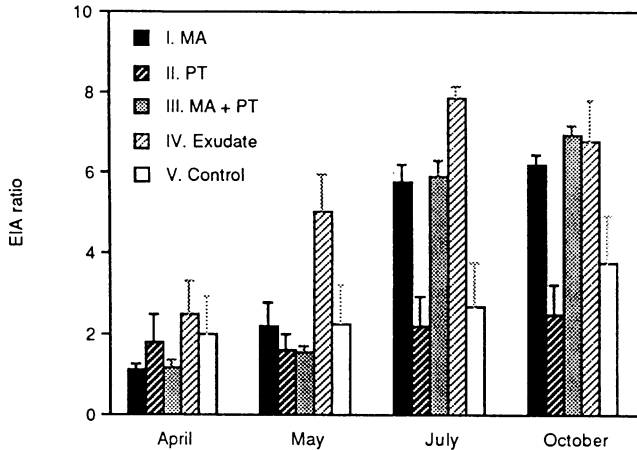


FIG. 3. Serum antibody response to *M. agassizii* in desert tortoises. Values are expressed as the enzyme immunoassay (EIA) ratios + standard errors. The EIA ratio is the ratio of the A_{405} of the sample to the A_{405} of the negative control. An EIA ratio of >2 was considered positive. Tortoises were inoculated in the nares with *M. agassizii* (MA; group I) *P. testudinis* (PT; group II), a combination of MA and PT (group III), exudate from ill tortoises (group IV), or sterile broth (control; group V). Serum values for April 1992 were obtained prior to challenge; all other samples were obtained postinfection. No significant differences were found among samples obtained in April. In May, group IV animals had significantly higher levels than the other groups ($P < 0.004$). In July and October, antibody levels in animals of groups I, III, and IV were significantly higher than those of animals in other groups ($P < 0.004$).

experimentally inoculated into the nares of healthy tortoises. Animals challenged with *M. agassizii* produced antibodies in response to the infection, and *M. agassizii* was isolated from the nares of animals which became clinically ill. The disease course as well as the specific immune response followed after a reasonable incubation period. Thus, we have fulfilled the majority of Henle-Koch-Evans postulates with regard to this disease. The lesions observed in the experimental infection studies were similar to those observed in the natural disease (8), and a range of lesions from mild to severe was seen.

A chronic infection was established, as evidenced by isolation of *M. agassizii* at 1 and 3 months postinfection. We have evidence (data not shown) that indicates some animals can remain infected after experimental challenge for up to 1 year. The transmission studies described in this report conclusively demonstrate that *M. agassizii* causes URTD in desert tortoises. Further, *P. testudinis* does not appear to have a role in the initiation of the disease, as indicated by the absence of clinical disease in challenged animals. A synergistic effect of *P. testudinis* and *M. agassizii* cannot be ruled out by this study but does not appear likely on the basis of severity of clinical signs observed in mixed infections.

The ability of exudate from donor tortoises to cause severe clinical disease may provide a clue as to transmission in the natural population. Direct contact and aerosol transmission of the mycoplasma is the most likely method of spread. However, one question that has yet to be addressed is the length of survival of *M. agassizii* in mucous droplets in the burrows of the tortoise and whether these could be a significant reservoir of infection. On the basis of other mycoplasmal infections, this is not a likely scenario but cannot be eliminated from consideration. The more severe disease seen in group IV animals may be a result of increased virulence after passage in the hosts.

Alternatively, loss of virulence after culture in the laboratory could also explain the observed differences in disease severity between the groups. Other factors which could explain the differences in disease severity include a difference between the virulence of the strain used in the study and that of the strain in the donor tortoises, as well as the presence of other contributory factors in the exudate. The exudate undoubtedly contained host inflammatory cells and potentially inflammatory mediators which might enhance the pathogenicity of the mycoplasma.

Antibody profiles demonstrated that the serological test developed may be very helpful in screening for disease. Animals which were challenged responded with a specific antibody response. We do not know the exact temporal sequence of the response, but it appears that in most cases a strong response was developed within 2 months or less of exposure. The response is directed toward a number of mycoplasmal antigens as indicated by Western blot (immunoblot) analysis, and many proteins appear to be shared among different strains of *M. agassizii* (data not shown).

Most animals with preexisting antibody which developed clinical disease also showed an increase in the amount of specific antibody present (data not shown). However, there were some animals which had levels of preexisting antibody which remained stable even though clinical disease was present. Preexisting antibody did not appear to protect against development of clinical disease in animals challenged intranasally, suggesting that a humoral response alone may not be adequate for protection. There were some animals with stable antibody levels that did not show signs of clinical disease. One of these animals was housed in the communal pen. No other tortoises housed with the antibody-positive tortoise developed antibody or disease. This suggests several interesting possibilities. First, any antibody-positive animal should be considered suspect. Secondly, animals which show increases in antibody over time are likely to be carriers or express disease. Thirdly, some animals may be antibody positive but not spread disease, like the tortoise in the communal pen. This is the first suggestion that some animals can clear *M. agassizii* from the respiratory tract and recover from, or never get, clinical disease. This issue can be resolved with a more sensitive measurement of microbial presence. A PCR detection system is currently under development in an attempt to address the question of exposure versus infection.

ACKNOWLEDGMENTS

We thank the staff at The Living Desert Museum, Palm Springs, Calif., without whom this study would have been impossible. We are especially grateful to Kristen Berry, Bureau of Land Management, Riverside, Calif., for her continued interest and encouragement.

This study was performed under amended federal permit PRT-747182. Funding for the study was provided by a grant (B812680) from The Nature Conservancy made possible by contributions from the development community in southern Nevada.

REFERENCES

1. Cassell, G. H., W. A. Clyde, and J. K. Davis. 1985. Mycoplasmal respiratory mycoplasmosis, p. 69-107. In S. Razin and M. F. Barile (ed.), *The mycoplasmas*, vol. IV. Academic Press, New York.
2. Evans, A. S. 1976. Causation and disease: the Henle-Koch postulates revisited. *Yale J. Biol. Med.* 49:175-195.
3. Evans, A. S. 1976. Limitations of Koch's postulates. *Lancet* ii:1277.
4. Fowler, M. E. 1977. Respiratory disease in captive tortoises, p. 89-98. In M. Trotter (ed.), *Proc. Desert Tortoise Council Symp.*
5. Gourlay, R. N., and S. B. Houghton. 1985. Experimental pneumo-

- nia in conventionally reared and gnotobiotic calves by dual infection with *Mycoplasma bovis* and *Pasteurella haemolytica*. Res. Vet. Sci. **38**:377–382.
6. **Hutchins, M., and U. S. Seal.** 1991. The role of veterinary medicine in endangered species conservation. J. Zoo Wildl. Med. **22**:277–281.
 7. **Jackson, O. F., and J. R. Needham.** 1983. Rhinitis and virus antibody titers in chelonians. J. Small Anim. Pract. **24**:31–36.
 8. **Jacobson, E. R., J. M. Gaskin, M. B. Brown, R. K. Harris, C. H. Gardiner, J. L. LaPointe, H. P. Adams, and C. Regiarrdo.** 1991. Chronic upper respiratory tract disease of free-ranging desert tortoises, *Xerobates agassizii*. J. Wildl. Dis. **27**:296–316.
 9. **Lawrence, K., and J. R. Needham.** 1985. Rhinitis in long term captive Mediterranean tortoises (*Testudo graeca* and *T. hermanni*). Vet. Rec. **117**:662–664.
 10. **Miller, R. Eric.** 1992. Zoo veterinarians—doctors on the ark? J. Am. Vet. Med. Assoc. **5**:642–647.
 11. **Nettles, V. F.** 1992. Wildlife diseases. J. Am. Vet. Med. Assoc. **5**:648–652.
 12. **Rosskopf, W. J., E. Howard, A. P. Gendron, E. Walder, and J. O. Britt.** 1981. Mortality studies on *Gopherus agassizii* and *Gopherus berlandieri* tortoises, p. 108–112. In K. A. Hashagan (ed.), Proc. Desert Tortoise Council Symp.
 13. **Schoeb, T. R., K. C. Kervin, and J. R. Lindsey.** 1985. Exacerbation of murine respiratory mycoplasmosis in gnotobiotic F344/N rats by Sendai virus infection. Vet. Pathol. **22**:272–282.
 14. **Schumacher, I. M., M. B. Brown, E. R. Jacobson, B. R. Collins, and P. A. Klein.** 1993. Detection of antibodies to a pathogenic mycoplasma in desert tortoises (*Gopherus agassizii*) with upper respiratory tract disease. J. Clin. Microbiol. **31**:1454–1460.
 15. **Snipes, K. P., and E. L. Biberstein.** 1982. *Pasteurella testudinis* sp. nov.: a parasite of desert tortoises (*Gopherus agassizii*). Int. J. Syst. Bact. **32**:201–210.
 16. **Snipes, K. P., E. L. Biberstein, and M. E. Fowler.** 1980. A *Pasteurella* sp. associated with respiratory disease in captive desert tortoises. J. Am. Vet. Med. Assoc. **177**:804–807.
 17. **Stadtländer, C. T. K.-H., H. L. Watson, J. W. Simecka, and G. H. Cassell.** 1991. Cytopathic effects of *Mycoplasma pulmonis* in vivo and in vitro. Infect. Immun. **59**:4201–4211.
 18. **Tully, J. G., D. L. Rose, R. F. Whitcomb, and R. P. Wenzel.** 1979. Enhanced isolation of *Mycoplasma pneumoniae* from throat washings with a newly modified culture medium. J. Infect. Dis. **139**:478–482.
 19. **Weinach, O. M., G. H. Snoeyenbos, C. F. Smeysers, and A. S. Soerjude-Liem.** 1985. Influence of *Mycoplasma gallisepticum*, infectious bronchitis, and cyclohexamide on chickens protected by native intestinal microflora against *Salmonella typhimurium* or *Escherichia coli*. Avian Dis. **28**:416–425.